

Analysis of saliva samples from oncological patients treated with 5-fluorouracil and leucovorin calcium by scanning electron microscopy with energy dispersive system

Marcelo Adrián Mazzeo¹, Jorge Alberto Linares¹, María Marcela López¹, Evelin Bachmeier¹, Fernando Martín Wietz¹, Víctor Galván^{2,3}, María Cecilia Valentinuzzi^{2,3}, José Alberto Riveros^{2,3}, Ana Finkelberg¹

¹Cátedra de Fisiología, Facultad de Odontología, Universidad Nacional de Córdoba, Córdoba, Argentina; ²Consejo Nacional de Investigaciones Científicas y Técnicas (CONICET), Córdoba, Argentina; ³Facultad de Matemática, Astronomía y Física (FaMAF), Universidad Nacional de Córdoba, Córdoba, Argentina

This work presents a chemical and morphological analysis of samples of saliva taken from patients who were under treatment with intravenous chemotherapy with 5-fluorouracil and leucovorin calcium. Samples of saliva were extracted from fifteen patients during the three stages of the treatment: The initial stage (previous to the chemotherapy), the intermediate stage (during the chemotherapy), and the final stage (twenty-one days after finishing the treatment). An amount of 50 µl was collected in each visit. Chemical contrast images were taken by means of scanning electron microscopy, and X-ray characteristic spectra were obtained from all the studied samples by using an energy dispersive system from all the studied samples. Images that correspond to the intermediate stage showed important differences with respect to the initial and final stages. In addition, X-ray spectra provided information about the present elements in saliva and their relative abundance allowed us to determine variations in the chemical composition. The back-scattered electron images and X-ray spectra from the intermediate stage showed clusters of crystals with fluorine content higher than those obtained in initial and final stages. This fact probably indicates the passage of metabolites of 5-fluorouracil and leucovorin calcium from the plasma to the oral cavity. This finding enhances the hypothesis proposed by other authors about the secondary effects of the drugs on the stomatognathic system such as oral mucositis, dysgeusia, and xerostomia with or without hyposalivation.

J Oral Pathol Med (2013)

Keywords: 5-fluorouracil; saliva; SEM-EDS

Introduction

For more than twenty years, developed countries have been promoting the use of saliva to the diagnosis of several diseases (1); some examples are: Sjögren syndrome, rheumatic diseases, sarcoidosis, cystic fibrosis, alcoholic cirrhosis, malnutrition, and breast carcinoma (2–5). The reason of this usefulness relies on the direct contact of the saliva with the blood serum, which offers a rapid method less traumatic for the patient. Oral fluids are good indicators of the healthiness of the individual. Previous works had analyzed oral fluids of women affected by osteoporosis (6) and smoking patients (7). They related the presence of some elements in the saliva with the severity of the disease. Changes in the gingival crevice fluid are used to diagnose and inspect the oral diseases such as: periodontal disease, caries, and fungus diseases (8, 9). Several medicines, including oncology medicines have been studied (10), with the use of gingival crevice fluid to inspect therapeutic drugs. The administration of 5-fluorouracil with its biomodulator, leucovorin calcium, to treat patients with diagnosis of metastatic colon carcinoma causes complications in the oral cavity (11). It had been reported that these agents are eliminated from the plasma and that the excretion of 5-fluorouracil in saliva after its intravenous administration can cause stomatitis in the upper part of the gastrointestinal tract (12), and other works have showed the presence of 5-fluorouracil in saliva (13, 14).

Mucositis is a possible complication caused by chemotherapy (15). It describes the inflammatory response of mucosal epithelial cells to the cytotoxic effects of drugs. Oral mucositis is a painful inflammation and ulceration of the mucous membranes lining the mouth cavity; about 40% of patients under chemotherapy contract mucositis (15). This pathology appears at 7–10 days after the initiation of treatment and last from 2–4 weeks after the treatment has finished (16). Scores and ulcerations can come down with virus, bacteria, and fungus. Pain and loss of taste perception make it more difficult to eat, which leads to weight loss.

Ulcers may act as a site for local infections (17). According to The World Health Organization, the mucositis can be classified in four grades (18). Pain, oral dysfunction, and gastrointestinal distress are commonly experienced by patients with mucositis, independently of the grade or severity. In grade 3 of oral mucositis, the patient is unable to eat solid food, and in grade 4 the patient is unable to consume liquids as well (19).

It had been shown that between 15–18% of patients treated with 5-fluorouracil and leucovorin calcium presented grade 3 or 4 of mucositis, which increases the risk of infections, affects nutrition, deteriorates the quality of life of the patient and, in several cases, it forces to interrupt the treatment, which increases the costs of hospitalization (20).

A previous study had been performed in twenty-five patients diagnosed with metastatic colon carcinoma and treated with intravenous administration of 5-fluorouracil, and leucovorin calcium had showed a decrement in basal salivary flow, changes in the pH of some components of saliva and variations in the indexes of oral health (11). Considering these references, the aim of this work was to find signs of the presence of the mentioned drugs or of their metabolites in the saliva using scanning electron microscopy with energy dispersive system (SEM-EDS).

The scanning electron microscopy (SEM) enables the observation and characterization of organic and inorganic materials from micrometer to nanometer scales. Through this technique, three-dimensional-like images of the surfaces of a wide range of materials can be obtained. The area to be observed was irradiated with a finely focused electron beam and the signals produced (secondary electrons, backscattered electrons, and characteristic X-rays) could be used to examine characteristics of the sample such as the topography of the surface and its composition.

The scanning electron microscopy in combination with an energy dispersive system (SEM-EDS) has gained a considerable importance in odontological studies (21, 22). These techniques besides being non-destructive, allow us to obtain the chemical composition of small amounts of samples with detection limits under 0.5% wt. The backscattered electron images (BEI) provide information about the mean atomic number; the regions of high average atomic number appear

brighter than regions of low atomic number. The changes in the gray level can be interpreted as regions of different chemical composition.

Materials and methods

Sample preparation

Saliva samples were extracted from fifteen adult patients who were diagnosed with colon carcinoma and treated with 5-fluorouracil and leucovorin calcium. This procedure was accomplished in three stages of the oncological treatment, as it is represented in Fig. 1. The first stage corresponds to a period before the treatment (these samples are referred as control group); the second stage corresponds to the treatment of chemotherapy, and the samples of the last stage were collected twenty-one days after the treatment had finished. The treatment consisted of six sessions of chemotherapy (5 days per session), which were separated by twenty-one days from each other. It must be mentioned that all patients presented similar clinical charts, and those who were under different medication, which may cause dry mouth, were discarded. Samples were taken from patients after more than two hours of fasting.

These patients were in orthostatic position without talking and with a previous rinse with distilled water. Patients were asked to deposit the saliva on a tube and then a fixed amount of 50 μ l was taken from the tube with a calibrated micropipette.

It is important to note that selecting the patients is a complicated task because they must fulfill some inclusion/exclusion criteria: Patients must not suffer from systematic pathologies, they must neither be smokers nor have dental implants. The patients cannot be under medication or treatment except under the drug of this study. All fifteen patients fulfilled the inclusion criteria of having one or more functional areas. The age cutoff was set at 55 years. The 43% of the patients were under that age and the 57% of them were over 55 years. The subjects under study were 8 male patients and 7 female patients. They participated voluntarily, and they had been informed of that they would be part of a clinical study.

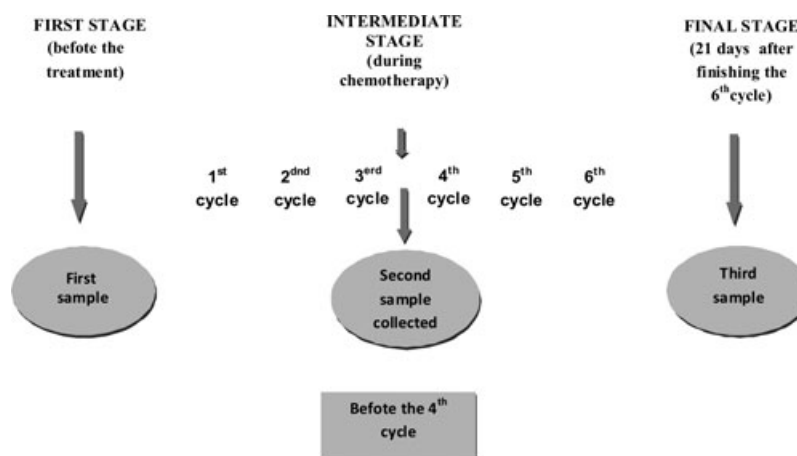


Figure 1 Schematic representation of the procedure used to collect the samples.

For SEM observation, the amount of 50 μl of saliva taken with the micropipette was deposited on a copper support and then dried in a stove at 37 $^{\circ}\text{C}$ during 24 h. After that procedure, the sample was covered with gold to prevent damages due to heating up and to charge accumulation effects caused by the electron beam.

Experimental conditions

Measurements were carried out in the LEO 1450 VP microscope installed at the LABMEM (Laboratory of Electron Microscopy and Microanalysis) of the National University of San Luis. The energy dispersive spectrometer EDS is an EDAX-Genesis 2000 with an ultrathin polymer window that makes possible the observation of all the elements of the periodic table from B ($Z = 5$) with a resolution of 129.2 eV for the Mn-K α line.

The SEM images and the X-ray spectra were obtained at 20 keV. The live time for the X-ray acquisition was 200 seconds, and the current fluctuations remained under the 1% of it in all cases. In order to obtain representative data from each sample, the different zones of the samples were scanned at a low magnification (70 X) and the results obtained at different zones were averaged.

Results and discussions

The composition of the 5-fluorouracil and leucovorin calcium drugs is: $\text{C}_4\text{H}_3\text{N}_2\text{FO}_2$ and $\text{C}_{20}\text{H}_{21}\text{CaN}_7\text{O}_7$, respectively. Thus, if the intermediate stage presented a higher concentration of F compared to the initial stage it could be inferred that metabolites of the drug would be present in saliva. The other elements present in the drugs such as C, H, and N have not been used as parameters because they are

usual constituents of organic materials. The concentration of these elements may vary from one patient to another according to metabolism processes and the presence of higher concentrations of Ca can be attributed to oral pathologies (23). Backscattered electron images representative of the three stages are shown in Fig. 2. Structural and compositional differences can be observed in the images, which corresponds to the samples at the initial (Fig. 2A) and the intermediate stage (Fig. 2C,D). The bright crystals in the intermediate stage (Fig. 2C,D) are clusters with mean atomic number different from the background. These agglomerates of crystals were observed in all samples from the intermediate stage with variable size, and they were not observed in the other stages. That fact allowed us to infer that those changes would be associated with the chemotherapy treatment because none of the considered patients took a different drug. Fig. 2 B corresponds to the final stage, showing no significant differences with the image regarding the initial stage.

The X-ray spectra that correspond to the initial stage and the intermediate stage in crystal zones and in the background are shown in Fig. 3. The spectra shown in Fig. 3 correspond to the same patient. Because initial levels of F (a sign of the presence of the drug) vary from one patient to another, relative intensities must be studied. A higher concentration of F is observed in the brightest zones from the second stage. It probably indicates the passage of metabolites of 5-fluorouracil and leucovorin calcium from plasma to oral cavity.

The most significant differences were found in Cl, K, and Ca (Fig. 3). The higher percentage of Ca in the intermediate stage is in agreement with the higher presence of dental calculus observed in this stage; this fact could indicate the presence of a severe periodontal disease such as periodontitis.

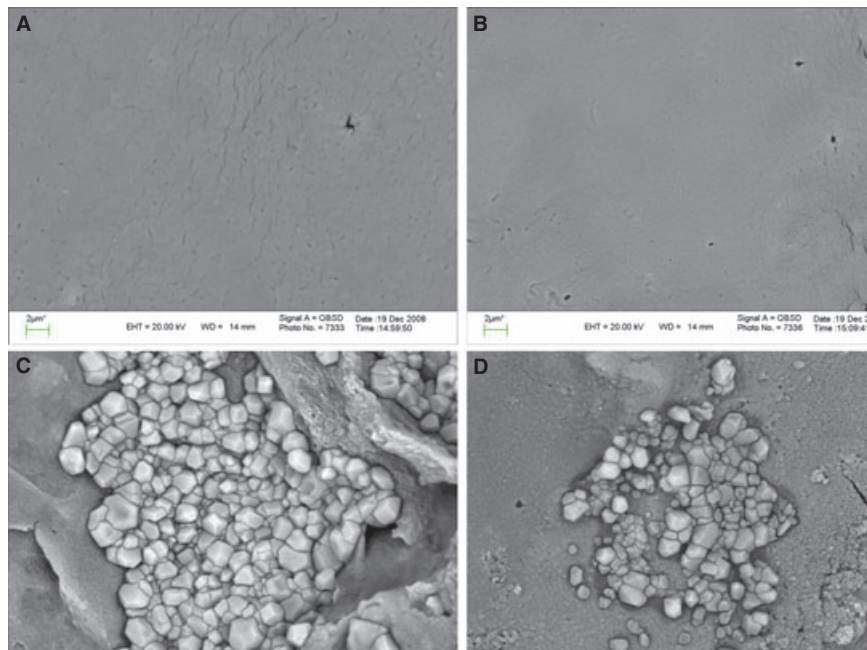


Figure 2 Images of backscattered electrons from saliva corresponding to the initial stage (A), final stage (B), and intermediate stage (C and D). Images C and D are from different patients.

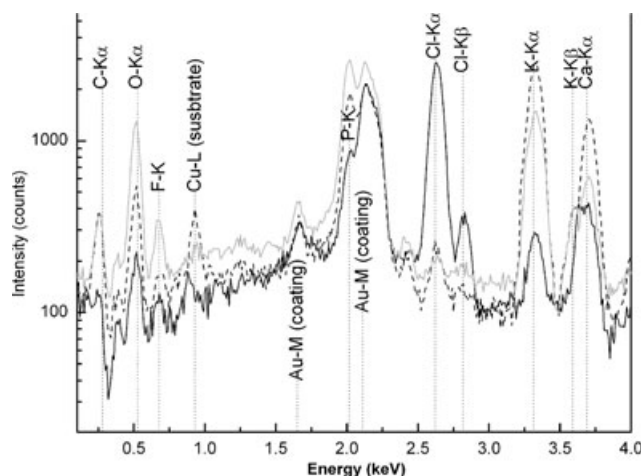


Figure 3 X-ray spectra corresponding to the initial stage (black line), the crystals to intermediate stage (gray line), and the background to intermediate stage (dashed line).

Table 1 Average values for intermediate and final stages of F and Ca relative intensities with respect to the initial stage ($IF/IF_{initial}$), ($ICa/ICa_{initial}$); the standard deviation of the average values is considered

	Intermediate stage crystal	Intermediate stage final stage	Background
$IF/IF_{initial}$	3.0 ± 0.9	1.4 ± 1.0	1.1 ± 1.0
$ICa/ICa_{initial}$	1.2 ± 0.6	1.7 ± 0.8	1.2 ± 0.7

The higher level of K in the intermediate stage could be related to the degeneration of tissues and the release of some cellular content that was caused by the development of some infections. This fact is in agreement with the presence of inflamed areas in the oral cavity of patients in the intermediate stage. Regarding the presence of Cl it must be mentioned that this element is known to be combined with H forming HCl, which is very volatile. It indicates that the Cl determination is not reliable.

In all cases, the salivary Ph was determined. Its mean values were 7.4 ± 0.1 for the initial stage, 7.1 ± 0.1 for the intermediate stage, and 7.5 ± 0.1 for the final stage.

Table 1 shows the average values of the quotients of characteristic X-ray line intensities of F and Ca relative to their intensities in the initial stage. These quotients were calculated for every patient to determine the average value. In the final stage, the variation of Ca and F with respect to the initial stage is not remarkable. The crystals present in the intermediate stage concentrate most of the excess of F, whereas the concentration of Ca rises only in the background.

The patients considered in this study presented grade 1 mucositis (18) in the intermediate stage of the treatment with 5-fluorouracil and leucovorin calcium. The fifteen patients did not suffer from mucositis at the moment when they were selected, so that the first sample was the control one. The reason was that in this way the presence of mucositis could be attributed to the chemotherapy, and the purpose was to evaluate the severity of this secondary effect in patients with no initial mucositis.

According to these results, the changes observed in the intermediate stage are consequence of the treatment with 5-fluorouracil and leucovorin calcium, because all patients were treated with equal conditions and they did not follow any other treatment or particular habit that could alter the results.

Both techniques, images by scanning electron microscopy and X-ray analysis, show that the differences are observed between the stages of the treatment. This is in agreement with clinical evaluation and with the alterations in the oral cavity observed in the intermediate stage.

Conclusions

The analysis of saliva extracted from patients before the treatment with cytotoxics (initial stage), during the treatment (intermediate stage), and after finishing the treatment (final stage) through BEI (chemical contrast) allowed us to observe changes in the chemical composition and microstructure. Higher concentrations of fluorine and calcium were observed in the samples extracted in the intermediate stage, indicating the presence of products from the metabolism of the drug in saliva. The heterogeneousness in chemical composition during the intermediate stage is revealed by the formation of clusters, which indicates the presence of strange substances in saliva.

These findings enhance the hypothesis proposed by other authors about the secondary effects of the drugs in the stomatognathic system such as mucositis, dysgeusia, and xerostomia with or without hyposalivation (24, 25).

The results obtained represent a powerful tool to analyze the secondary effects on the oral cavity of the patients in treatment with cytotoxics. It allowed us to assume that metabolites of 5-fluorouracil and leucovorin calcium are present in saliva, and they alter the oral cavity and the upper part of the gastrointestinal tract. As a consequence of this, the life quality of patients is seriously affected because these alterations hinder the ingestion and they cause subsequent nutrition problems and the deterioration of organic systems.

Considering these findings, some precautions should be taken into account when patients are submitted to this treatment in order to diminish the expected complications and to offer appropriate steps to alleviate the symptoms.

The scanning electron microscopy is a reliable technique to study this kind of samples and to obtain information about chemical composition with the energy dispersive system and about the mean atomic number of the sample through the analysis of BEI. Besides, the topographic contrast shows how crystals form clusters in the intermediate stage.

At present, more samples are being collected to continue with this study. This work is part of a clinical research whose objective is to analyze different oncology drugs in order to determine which of them give better results with minimum side effects.

References

1. Wong D. Salivary diagnostics powered by nanotechnologies, proteomics and genomics. *J Dent Assoc* 2006; **137**: 313–21.
2. Fox PC. Acquired salivary dysfunction. Drugs and radiation. *Ann N Y Acad Sci* 1998; **842**: 132–7.

3. Bagan JV, Alapont L, Sanz C, del Olmo JA, Morcillo E, Cortijo J. Dental and salivary alterations in patients with liver cirrhosis: a study of 100 cases. *Med Clin (Barc)* 1998; **111**: 125–8.
4. Ben-Aryeh H, Serouya R, Kanter Y, Szargel R, Laufer D. Oral health and salivary composition in diabetic patients. *J Diabetes Complications* 1993; **7**: 57–62.
5. Bigler LR, Streckfus CF, Copeland L, et al. The potential use of saliva to detect recurrence of disease in women with breast carcinoma. *J Oral Pathol Med* 2002; **31**: 421–31.
6. Sanchez HJ, Valentinuzzi MC, Grenon M, Abraham J. Total reflection X ray fluorescence analysis of oral fluids of women affected by osteoporosis and osteopenia. *Spectrochim Acta B* 2008; **63**: 1485–8.
7. Abraham JA, Sanchez HJ, Grenon M, Valentinuzzi MC. Influence of smoking in the elemental composition of oral fluids. *X Ray Spectrom* 2010; **39**: 372–5.
8. Todorovic T, Dozic I, Vicente Barrero M, et al. Salivary enzymes and periodontal disease. *Med Oral Patol Oral Cir Bucal* 2006; **11**: E115–9.
9. Kaufman E, Lamster IB. The diagnostic applications of saliva. A Review. *Crit Rev Oral Biol Med* 2002; **13**: 197–212.
10. Takahashi T, Fujiwara Y, Sumiyoshi H, Isobe T, Yamaoka N, Yamakido M. Salivary drug monitoring of irinotecan and its active metabolite in cancer patients. *Cancer Chemother Pharmacol* 1997; **40**: 449–52.
11. Mazzeo MA, Linares JA, Campos ML, et al. Oral signs of intravenous chemotherapy with 5-fluorouracil and leucovorin calcium in colon cancer. *Med Oral Patol Oral Cir Bucal* 2009; **14**: E108–13.
12. Celio LA, Digregorio GJ, Ruch E, Pace J, Piraino AJ. Doxorubicin and 5-fluorouracil plasma concentrations and detectability in parotid saliva. *Eur J Clin Pharmacol* 1983; **24**: 261–6.
13. Celio LA, Digregorio GJ, Ruch E, Pace JN, Piraino AJ. 5-fluorouracil concentrations in rat plasma, parotid saliva, and bile and protein binding in rat plasma. *J Pharm Sci*, 1983; **72**: 597–9.
14. Milano G, Thyss A, Santini J, et al. Salivary passage of 5-fluorouracil during continuous infusion. *Cancer Chemother Pharmacol* 1989; **24**: 197–9.
15. Barasch A, Peterson DE. Risk factors for ulcerative oral mucositis in cancer patients: unanswered questions. *Oral Oncol* 2003; **39**: 91–100.
16. Sonis ST. Oral mucositis in cancer therapy. *J Support Oncol* 2004; **2**(6 suppl 3): 3–8.
17. Duncan M, Grant G. Oral and intestinal mucositis-causes and possible treatments. *Aliment Pharmacol Ther* 2003; **18**: 853–74.
18. World Health Organization. *Handbook for reporting results of cancer treatment*. Geneva, Switzerland: World Health Organization, 1979.
19. Poplin EA, Benedetti JK, Estes NC, et al. Phase III Southwest Oncology Group 9415/Intergroup 0153 randomized trial of fluorouracil, leucovorin, and levamisole versus fluorouracil continuous infusion and levamisole for adjuvant treatment of stage III and high-risk stage II colon cancer. *J Clin Oncol* 2005; **23**: 1819–25.
20. Harris DJ. Cancer treatment-induced mucositis pain: strategies for assessment and management. *Ther Clin Risk Manag* 2006; **2**: 251–8.
21. Gil-Chavarria I, Garcia-Garcia R, Reyes-Gasga J. Comportamiento estructural de la unión esmalte-dentina en dientes humanos: un modelo mecánico-funcional. *Acta Microscopica* 2008; **17**: 34–47.
22. Schüpbach P, Oppenheim FG, Lendenmann U, Lamkin MS, Yao Y, Guggenheim B. Electron-microscopic demonstration of proline-rich proteins, statherin and histatins in acquired enamel pellicles *in vitro*. *Eur J Oral Sci* 2001; **109**: 60–8.
23. Feldman RS, Bravacos JS, Rose CL. Association between smoking different tobacco products and periodontal disease indexes. *J Periodontol* 1983; **54**: 481–7.
24. Davies AN, Broadley K, Beighton D. Salivary gland hypofunction in patients with advanced cancer. *Oral Oncol* 2002; **38**: 680–5.
25. Jensen SB, Pedersen AM, Reibel J, Brunner N, Nauntofte B. Xerostomia and Hypofunction of the salivary glands in cancer therapy. *Support Care Cancer* 2003; **11**: 207–25.

Acknowledgements

Authors would like to thank the staff of the Servicio de Hematología y Oncología from Sanatorio Allende (Córdoba, Argentina).